Quick Clinical Reference Chart for Visual Inspection of the Oral Cavity to Detect Precancerous Lesions and Invasive Cancers

Regional Cancer Centre (RCC), Trivandrum, India

World Health Organization (WHO)
International Agency for Research on Cancer (IARC)

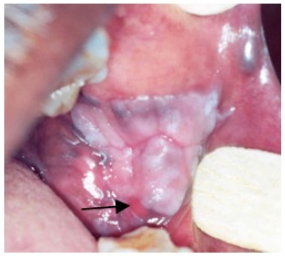

Homogeneous leukoplakia with central fissuring in the left buccal mucosa.

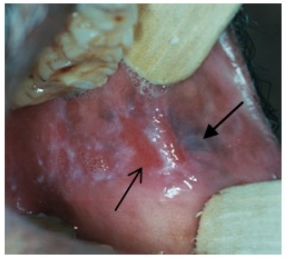

Non-homogeneous leukoplakia (ulcerated leukoplakia) left buccal mucosa with an ulcerated area in the centre (thin arrow) surrounded by white patches and note the tobacco induced pigmentation anteriorly (thick arrow).

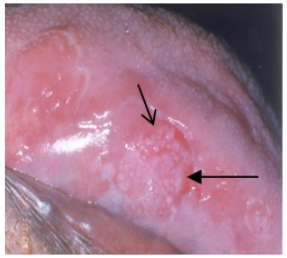

Non-homogeneous leukoplakia (nodular leukoplakia) right margin of the tongue: note the white nodules (thin arrow) on an erythematous base (thick arrow).



Non-homogeneous leukoplakia (verrucous leukoplakia) hard palate: a diffuse white patch can be seen involving the left and middle portions of the hard palate with warty projections.



Erythroplakia right buccal mucosa: note the red, velvetty oval lesion



Restricted mouth opening in a patient with oral submucous fibrosis (SMF); note the blanching and extensive depapillation of the tongue.

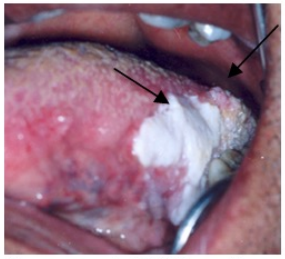

Homogenous leukoplakia on the right lateral margin of tongue from which a proliferative growth is seen arising posteriorly; biopsy from this area confirmed the presence of a well differentiated squamous cell carcinoma.



Ulcerated leukoplakia left lateral margin tongue with nodular areas which biopsy showed squamous cell carcinoma.

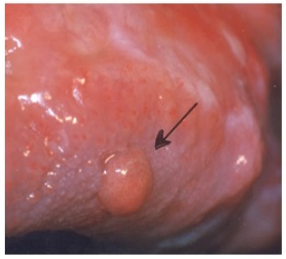

Nodular leukoplakia in the left lateral margin of the tongue harbouring a proliferative growth.



Verrucous leukoplakia with invasive oral cancer at the centre of the lesion (arrow) where a growth can be appreciated, indicating malignant transformation of the leukoplakia.

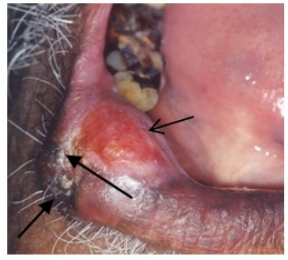

Erythroplakia of the lower lip: note the crusting extending to the vermillion border (thick arrows), which on biopsy revealed well differentiated squamous cell carcinoma.

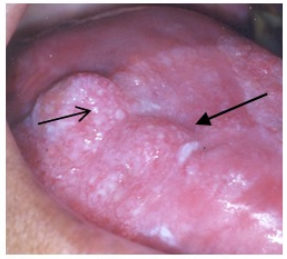

Submucous fibrosis of the tongue with surface nodularities (thin arrows) and multiple, proliferative surface growths (thick arrows) which on biopsy showed well differentiated squamous cell carcinoma.

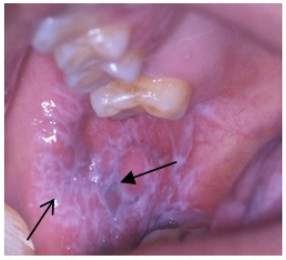

Lichen planus in the right buccal mucosa: note the annular rings (thin arrow) with raised white Wickham's striae (thick arrow).

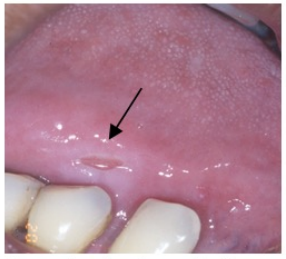

Traumatic ulcer (arrow) in the right lateral margin of tongue caused by irritation of the dorso - lingual cusp of the mandibular canine teeth.



Traumatic ulcer with malignant transformation left lateral margin tongue: note the ulcerative lesion with rolled out borders caused by chronic irritation from the root stumps of the left mandibular 2nd premolar and 1st molar teeth.



Exophytic proliferative growth in the left lateral margin of the tongue: note the co-existing depapillation of the tongue.



Advanced, ulceroproliferative invasive oral cancer in the right lateral margin of the tongue: note the co-existing submucous fibrosis.



Malignant melanoma left buccal mucosa: note the hyperpigmented patch with nodular areas.